

# A sequential extended regional maxima transformation with contrast-based criterion for image segmentation

**Abstract.** This paper describes the sequential extended regional maxima transformation combined with the contrast-based criterion for establishing a sub-optimal  $h$ -value. This method is applied to computed tomography angiography and histological image segmentation. The presented method is effective for high and low contrasted arteries, which are detected in 94.3% exactly and in 97.7% with area tolerance, and also for cell nuclei segmentation with near 95% of accuracy.

**Streszczenie.** W pracy przedstawiono zastosowanie transformaty rozszerzonych maksimów lokalnych połączonej z kryterium opartym na kontraście celem ustalenia suboptymalnej wartości parametru  $h$ . Zaproponowana metoda została wykorzystana do analizy obrazów tomografii komputerowej naczyń oraz obrazów histologicznych. Okazała się ona wysoce skuteczna dla identyfikacji naczyń z różnym poziomem zakontrastowania, pozwalając na około 96% ich rozpoznawalność, jak również blisko 95% skuteczność w segmentacji jąder komórek w obrazach mikroskopowych. (Sekwencyjna transformata rozszerzonych maksimów lokalnych z kryterium opartym na kontraście z zastosowaniem do segmentacji obrazów).

**Keywords:** image processing, mathematical morphology, computed tomography, pathomorphology.

**Słowa kluczowe:** przetwarzanie obrazów, morfologia matematyczna, tomografia komputerowa, patomorfologia.

## Introduction

The extended regional maxima is a mathematical morphology transformation addressed to detection of the region which locally dominates in the grey scale image. For the assumed altitude parameter  $h$  all regions augmented from their background at minimum  $h$  value are extracted. When the procedure is unambiguously defined and well known, the altitude parameter is commonly selected a priori or in validation process as a one fixed value. This selection can be inadequate for many objects, especially recognizable from the background on different grey level. We meet with this problem in artery analysis in computerized tomography angiography (CTA). That method of visualization is based on contrast to blood injection and permit an artery lumen enhancement and visualization. Also, similar problem exists in the histological images when the cell nuclei segmentation is often not properly. The increase of the precision of nuclei outline allow to a cell area analysis and approximation of a number of nuclei in cell clusters.

Computed tomography scanners, by virtue of their high resolution, permit imaging of the peripheral arteries. The current generation of 64-detector-row CT scanners and the development of 3D rendering techniques have made peripheral CT angiography a powerful tool for noninvasive imaging and treatment planning of endovascular and open surgery. Preoperative arteries evaluation is crucial in planning surgery [1]. Actually, CTA is recommended in trauma centres as a diagnostic procedure in trauma patients. Contrast induced nephropathy is a serious drawback of this exam. Because of this ultrasound or magnetic resonance imaging methods for elective patients should be performed [1]. Nowadays, the number of vascular patient considered for minimally invasive surgical procedures is still growing. So the tendency to facilitate the evaluation of arteries and vascular access is still observed. The potential possibility of automatic or semiautomatic arteries' analysis could be an interesting and useful tool. In this way, the preoperative assessment of the most popular vascular access - it means ilio-femoral segment, forms the crucial part of preoperative management [2].

In the literature, can be found a various approaches to a vessel segmentation from the images. Classical techniques in that category include 2D parametric active contours, as used in [3,4]. In [5] a grey-level hit-or-miss transform in 3D space with a set of vessel forward-background masks was

defined and applied. This method is connected with the assumed vessel size, that limited them to main vessels. The studied here peripheral arteries are very thin, that make it difficult to define the proper set of masks. In the paper [2] the artery extraction method based on the extended regional maxima was proposed for segmentation of the aorta, iliac and femoral arteries. Its results relate only to the differentiation of the contrasted artery lumen from the surrounding soft tissue, not to the artery cross-section area. This is the main advantage of this approach compared to the other ones. Even in case of substantial size of the femoral arteries, can be found thin subjects difficult to recognition in the image. However, the effect of application of extended regional maxima transform highly relates from the assumed amount of local convexity value  $h$ . When for the main arteries the selection of a one sub-optimal value can be successfully done, a thin artery can be lost.

In the case of the pathological microscopic images the main task is the appropriate recognition of the cells. This step is necessary for quantitative evaluation of many antibodies, marked with the specific staining. The precision of a separation of the separately distributed cells can give a useful measure to control the segmentation of overlapped ones. In the paper [6] the sequential thresholding was proposed with the cell area criteria to establish the most useful threshold value. This approach offers a well separation of the cells, however not the best outlined of their nuclei. Thus, it is necessary consider using other criteria for possible better segmentation of the cell nuclei.

In this paper the authors focused on the sequential algorithm based on the extended regional maxima transform. Inclusion of the gradient aim function offers a useful tool for object segmentation from the images. The schemes for CTA and histological images were proposed and evaluated.

## Materials and Methods

The twenty images of lower limbs with various number, size and contrast intensity peripheral arteries was selected from tomograms of twenty patients at different stages of atherosclerotic changes in the iliac and femoral arteries, treated in the Department of Vascular Surgery. For the second research data, the twenty meningioma images were selected come Department of Pathomorphology, both from Military Institute of Medicine in Warsaw.

The extended regional maxima transformation comes from the mathematical morphology and it is addressed to detection of the local maxima regions, whose altitude with respect to their surroundings is higher than the assumed  $h$  value. The realization of them based on h-maxima transformation. The h-maxima transformation suppresses all maxima in the grey scale image whose altitude is lower to a given threshold level  $h$ . It is achieved by performing the reconstruction using the iterated dilation  $\delta$  of the marker  $f - h$  under the mask as the original image  $f$ , where  $f - h$  is obtained decreasing all pixel intensities by  $h$ . This operation can be written as [6]

$$(1) \quad HMAX_h(f) = R_f^\delta(f - h)$$

The regional maxima of the image at elevation represents a connected components of pixels with the value  $t$  for which the external boundary pixels have values strictly less than  $t$ , and this operation may be described by the following expression [6]:

$$(2) \quad RMAX(f) = f - R_f^\delta(f - 1)$$

The extended regional maxima is defined as the regional maxima described by the corresponding h-maxima transformation [6]:

$$(3) \quad EMAX_h = RMAX[HMAX_h(f)]$$

As a supported measure of appropriate artery contour detection via EMAX, we suggest the usage of the image gradient and calculation of the average of them on the detected contour. An h-value for a maxima of measure of contour gradient can be taken as the sub-optimal parameter. The formula of applied external gradient can be written as [6]

$$(4) \quad \rho^+ = \delta_{SE}(f) - f$$

where  $SE$  is a structuring element, here selected as a disk object with radius equals 1 pixel.

In the CTA image analysis a problem is to distinguish a pre-selection of the potential arteries. Only these object should be examined to establish the proper h-value. Based on tests and our knowledge, this task can be solved by extraction of the objects which locally dominate in the image. We applied EMAX with h equals 150 in grey scale units and removed the objects which area were larger than 100 pixels. In such way we obtained the markers of only thin arteries.

In the cell nuclei segmentation task the proposed procedure was applied to the immunonegative cells. The processed images, in grey-scale, were obtained by a differentiation of blue and green components of the RGB images. The initial markers were obtained via EMAX with the fixed parameter  $h = 20$ . Only the cells marked in such a way were subsequently segmented.

## Results

The examined images were evaluated in the following way: for each image the thin arteries were found and marked manually by expert. Next, the image was analysed fully automatically by the software and the results were compared. The agreement between the number of recognized arteries was evaluated. Additionally, expert evaluated the correctness of artery cross section areas obtained from the software. If the result was to accept, the artery was counted as the properly outlined. If the obtained

artery cross-section area was overestimated or underestimated, such artery was counted as approximately outlined. The detailed results for twenty images are presented in the Table 1. The level of correctly recognized arteries was 94.3 % (Accuracy 1) whereas 97.7 % (Accuracy 2) of manually detected arteries were generally extracted from the images by the software. The sample of graphical results of two cases are presented in Figure 1.

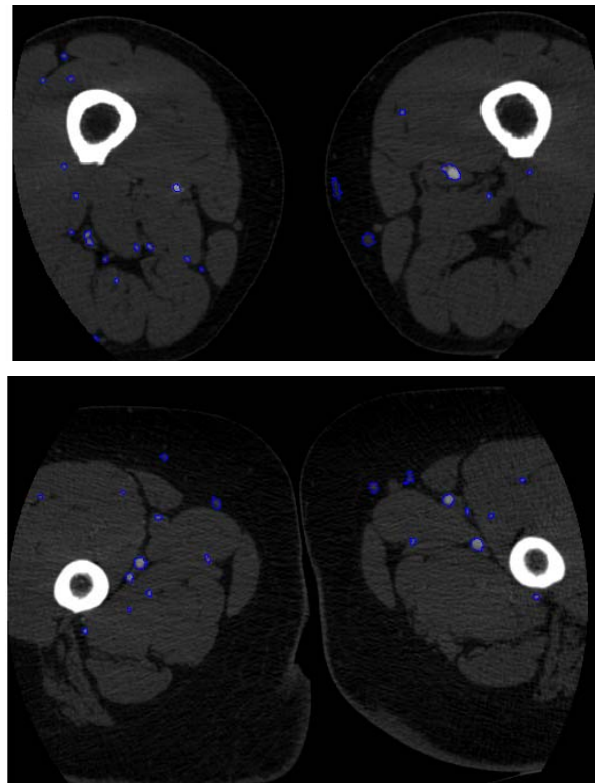


Fig.1. The results of artery segmentation in two cases of CT scans

Table 1. The results of artery recognition on CTA images

No of image	Manual count of arteries	No of correctly recognized arteries	No of approximately recognized arteries	Accuracy 1	Accuracy 2
1	20	18	2	90%	100%
2	30	29	0	96.7%	96.7%
3	29	25	3	86.2%	96.7%
4	20	20	0	100%	100%
5	25	24	1	96%	100%
6	21	21	0	100%	100%
7	22	20	2	90.9%	100%
8	22	22	0	100%	100%
9	20	19	0	95%	95%
10	30	27	2	90%	96.7%
11	19	18	0	94.7%	94.7%
12	17	16	0	94.1%	94.1%
13	22	18	4	81.8%	100%
14	19	17	1	89.5%	94.7%
15	11	11	0	100%	100%
16	33	30	0	90.9%	90.9%
17	23	22	1	95.7%	100%
18	19	19	0	100%	100%
19	20	19	0	95%	95%
20	17	17	0	100%	100%
Mean				94.3%	97.7%

It should be noted that in the evaluation of arterial tree the marks of thin arteries could be obtained from the previous image in CTA sequence in tracking process. Of course, each arterial division into the thinness ones is a beginning point for track a new artery. Such artery can be

tracked until it enters the capillaries, loses the continuity of flow or back connects to the main artery. The last case is common especially when a part of main artery is fully occluded.

The graphical result of nuclei segmentation in one field of view is presented in Fig. 2. The most of nuclei were segmented properly with accurate located outlines. The obtained accuracy with 96.4% of recognized cells was very high and only few cells were omitted due to existence of clusters. Such cells can be segmented in the additional process i.e. it was presented in the paper [7].

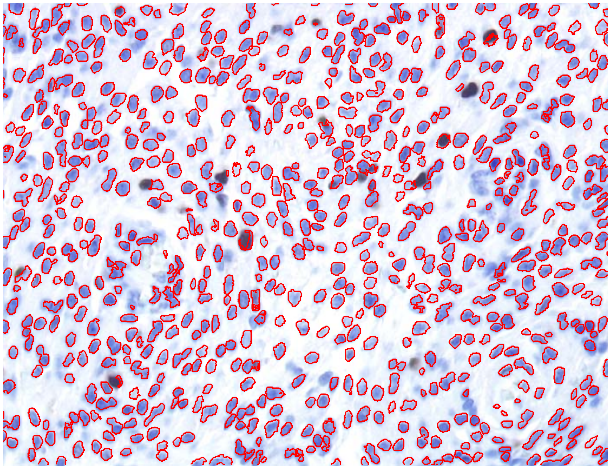


Fig.2. The results of blue cell nuclei segmentation

### Conclusion

The paper has presented the new approach to automatic segmentation of objects, applied for recognition of the thin arteries from the CTA images and the cell nuclei from the histological images. The sequence of extended regional maxima with the contour gradient measure allows to automatic selection of the most adequate h-value. The presented method is very effective with the detection rate about 95%.

### Acknowledgments

This work has been partially supported from the National Centre for Research and Development (PBS2/A9/21/2013 grant).

### REFERENCES

- [1] Fleischmann, D., Hallett, R.L., Rubin, G.D, CT Angiography of Peripheral Arterial Disease, *Journal of Vascular and Interventional Radiology.*, 17 (2006), 3 - 26
- [2] Markiewicz, T., Dziekiewicz, M., Maruszynski, M., Boguslawska-Walecka, R., Kozłowski, W.: "Recognition of atherosclerotic plaque and their extended dimensioning with use of the computerized tomography angiography imaging". *Int J Appl Math Comp Scie*, 1 (2014), 33-47
- [3] Hernandez-Hoyos, M., Segmentation anisotrope 3D pour la quantification en imagerie vasculaire par rTsonance magnTtique (in french). Ph.D. Thesis, Ecole Doctorale des Sciences de l'IngTnieur de Lyon, CREATIS UMR-CNRS 5515, Lyon, France, 2002
- [4] Li, R., Ourselin, S., Accurate curvilinear modeling for precise measurements of tubular structures. *In: Proc. Digital Image Comput.: Tech. Appl.* (2003), 243–252
- [5] Naegel, B., Passat, N., Ronse, C., Grey-level hit-or-miss transforms. Part II. Application to angiographic image processing. *Pattern Recogn*, 40(2) (2007), 648–58
- [6] Soille, P.: „Morphological Image Analysis, Principles and Applications“. Berlin, 2003,
- [7] Markiewicz, T., Osowski, S., Patera, J., Kozłowski, W.: "Image processing for accurate cell recognition and count on histological slides". *Anal Quant Cytol Histol*, 26 (2006), 281-92.

**Authors:** dr hab. inż. Tomasz Markiewicz, Politechnika Warszawska, Instytut Elektrotechniki Teoretycznej i Systemów Informacyjno-Pomiarowych, ul. Koszykowa 75, 00-662 Warszawa, oraz Wojskowy Instytut Medyczny, Zakład Patomorfologii, ul. Szaserów 128, 04-141 Warszawa, E-mail: [markiewt@iem.pw.edu.pl](mailto:markiewt@iem.pw.edu.pl); dr hab. n. med. Mirosław Dziekiewicz, Wojskowy Instytut Medyczny, Klinika Chirurgii Naczyniowej i Endowaskularnej, ul. Szaserów 128, 04-141 Warszawa, E-mail: [dziekiewicz@wp.pl](mailto:dziekiewicz@wp.pl); prof. dr hab. n. med. Wojciech Kozłowski, Wojskowy Instytut Medyczny, Zakład Patomorfologii, ul. Szaserów 128, 04-141 Warszawa, E-mail: [wojciechkozlowski@interia.pl](mailto:wojciechkozlowski@interia.pl).